



باسمه تعالی



# Surgical considerations on Crown Lengthening procedure

**Dr. Mojtaba Bayani**

Periodontist, Implantologist

Assistance professor of periodontics department

Arak University of Medical Sciences

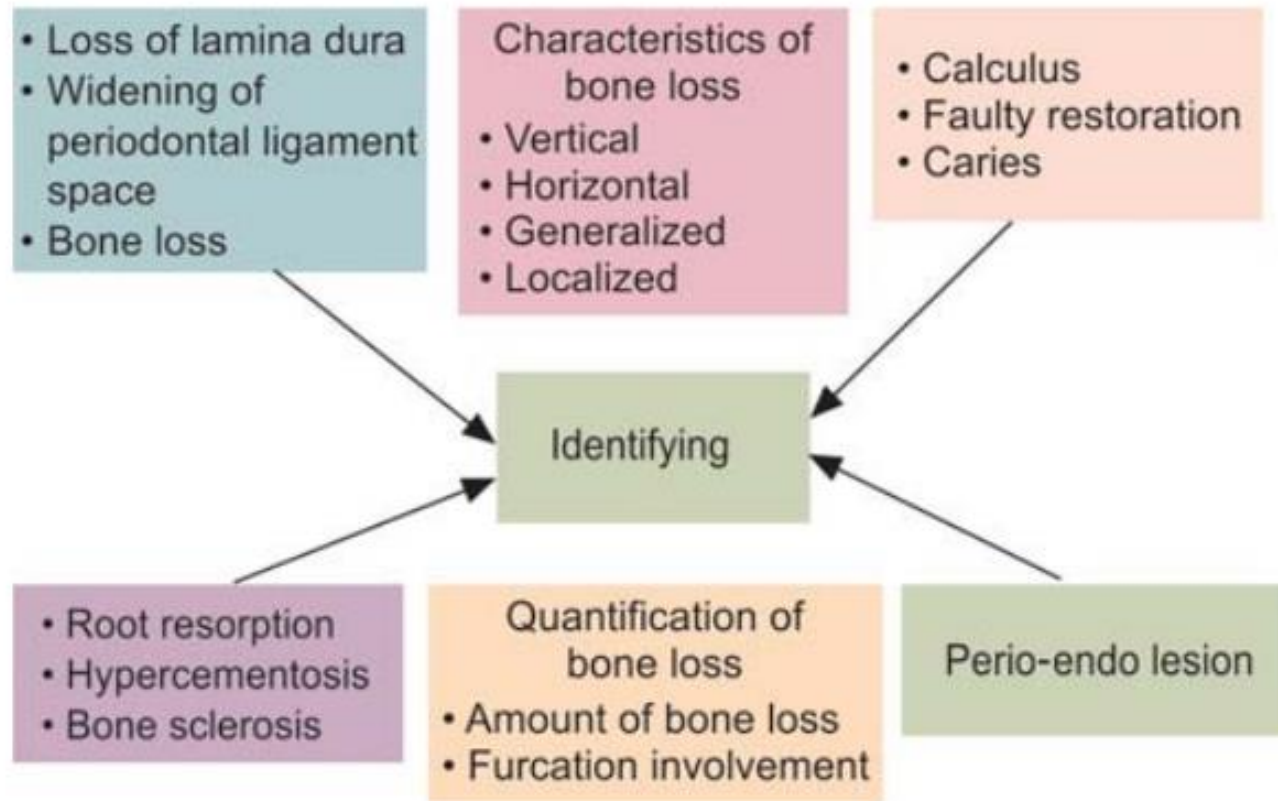
Mar 2021

Sunday, February 28, 2021

Presented by Dr. Mojtaba Bayani

# Radiographic assessment

## Flow Chart 1: Role of radiographs in periodontal disease at a glance

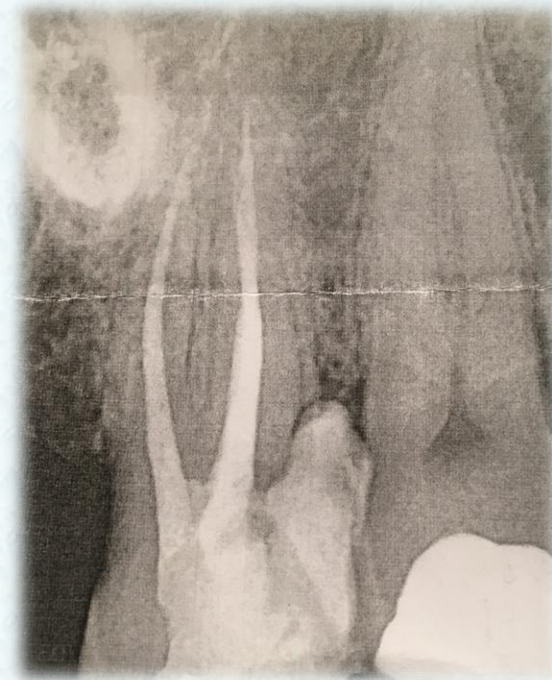



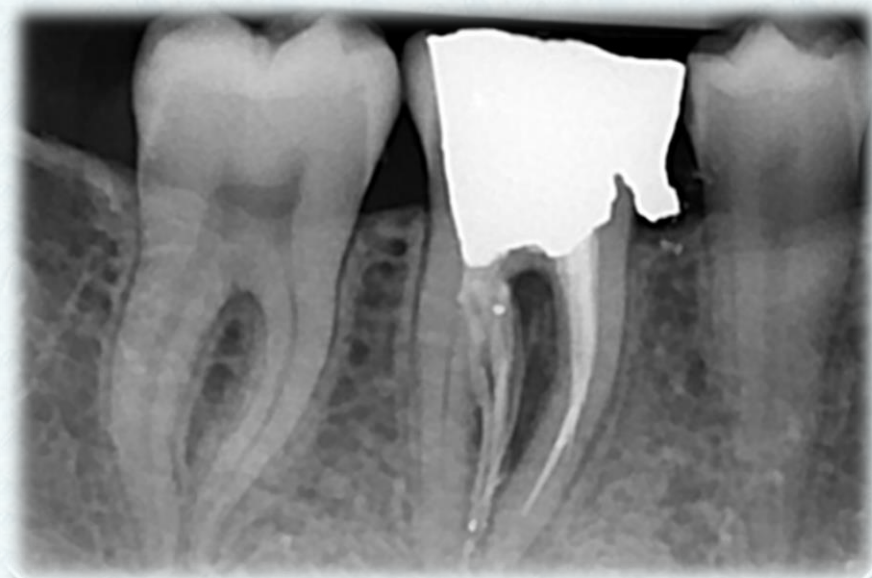# clinical cases

## DDIs

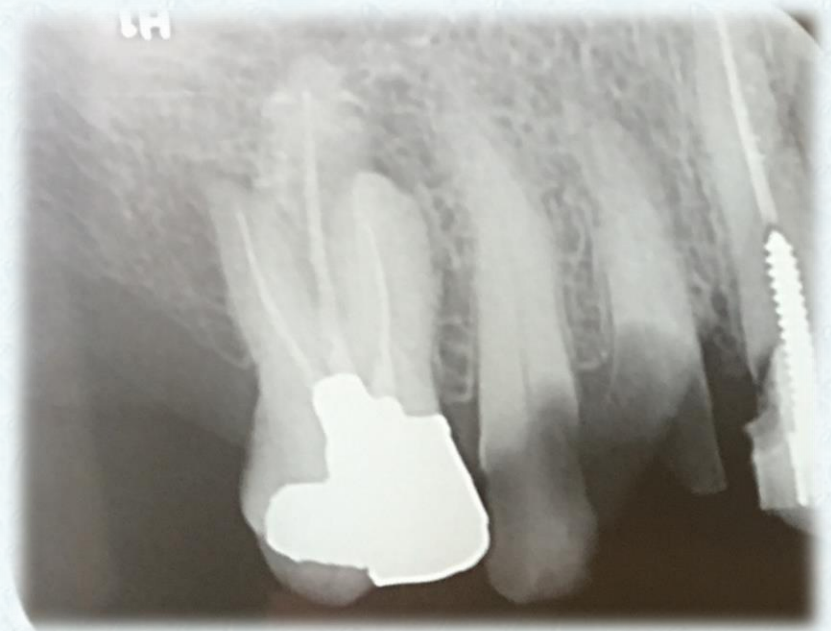
- Sever caries
- Restorability
- Adjacent tooth
- Accessibility



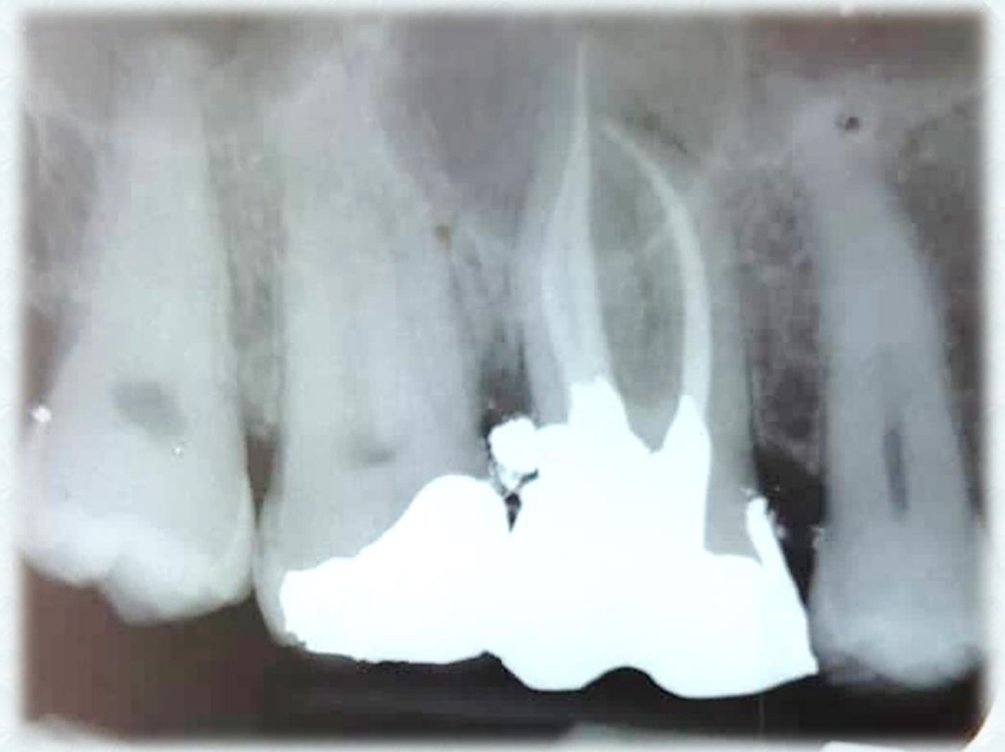- Accurate PA radiography
- hopeless prognosis



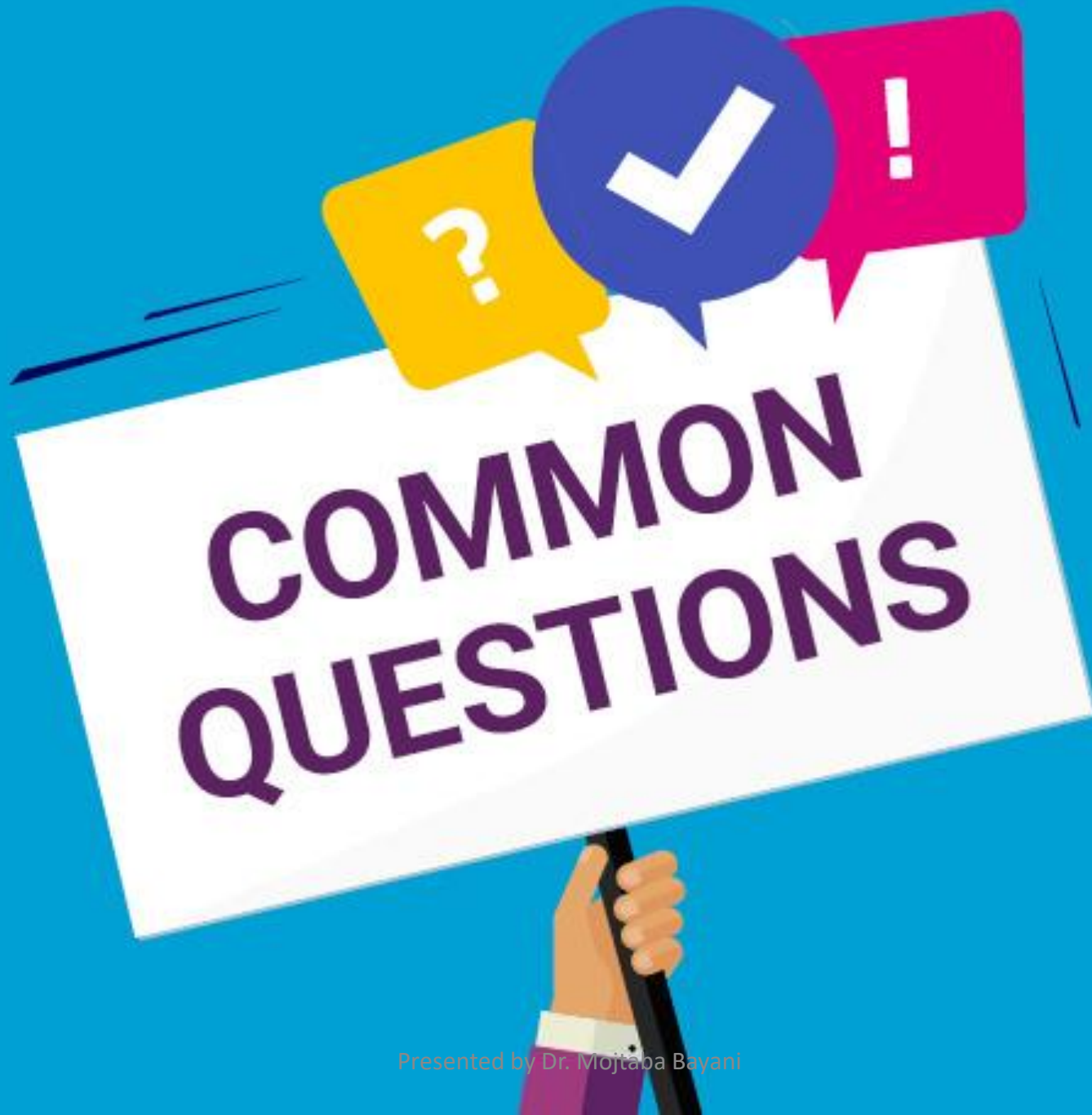- Endodontically consultant
- Broad field of view
- Master plan
- Maxillary sinus position



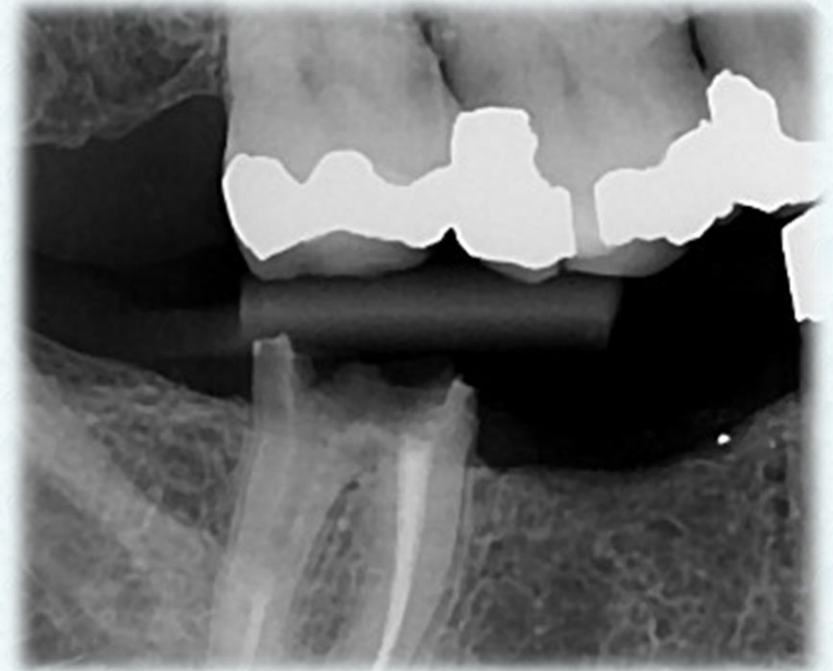
- Adjacent tooth
- Pocket formation in distal aspect
- Future crown length
- Maxillary sinus position



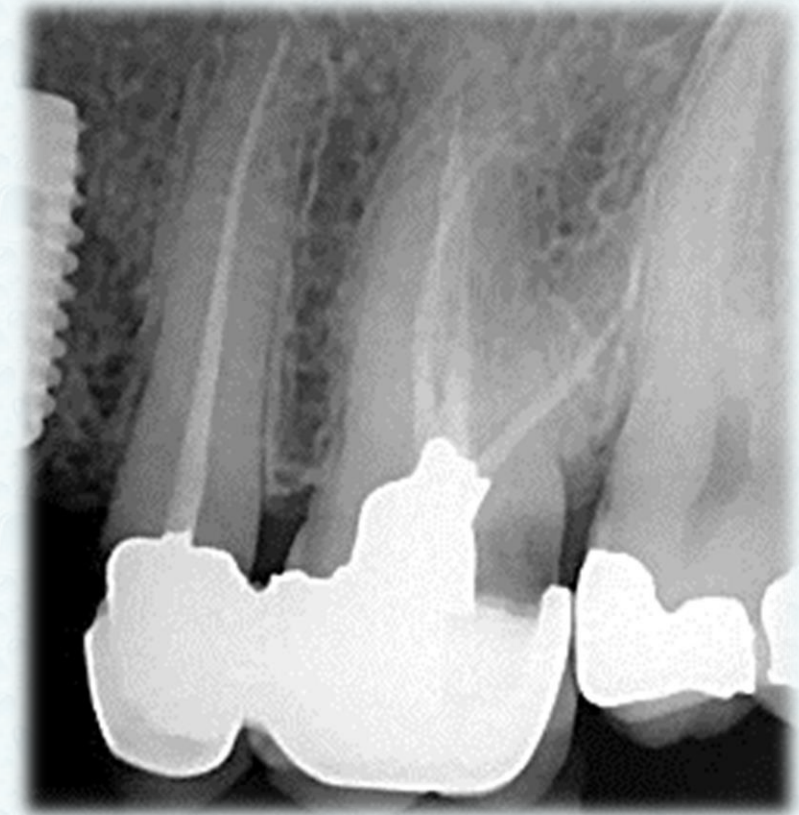




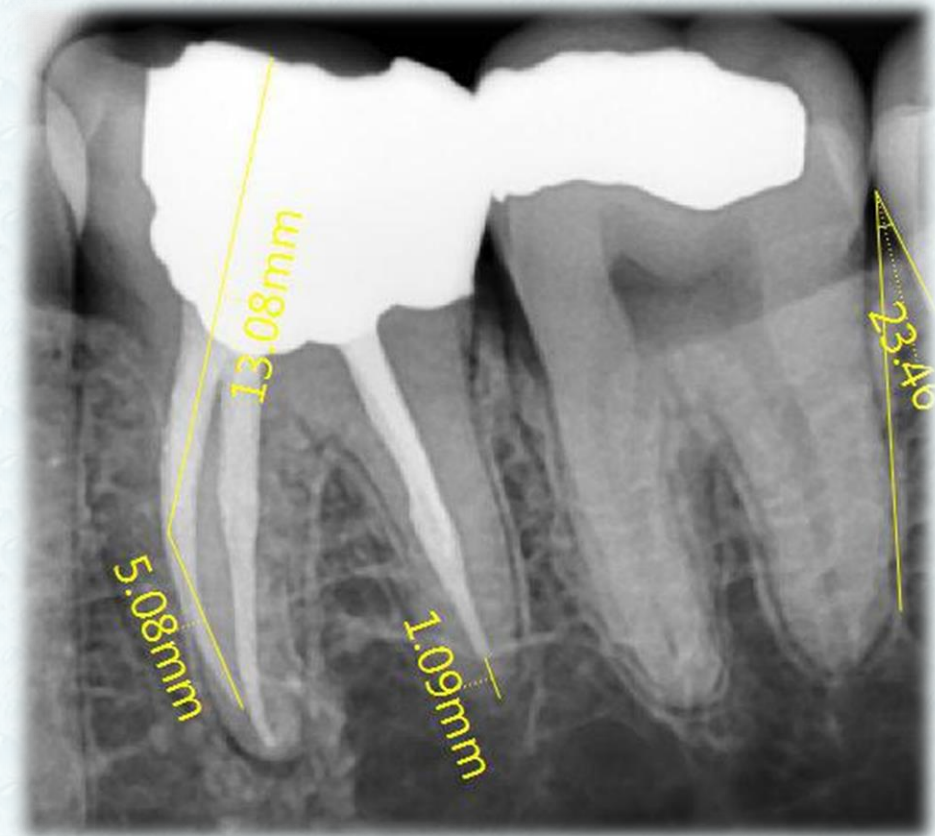
- Accurate PA radiograph
- Endodontically consultant
- Restorability
- Master plan
- Accessibility
- Inferior alveolar nerve position



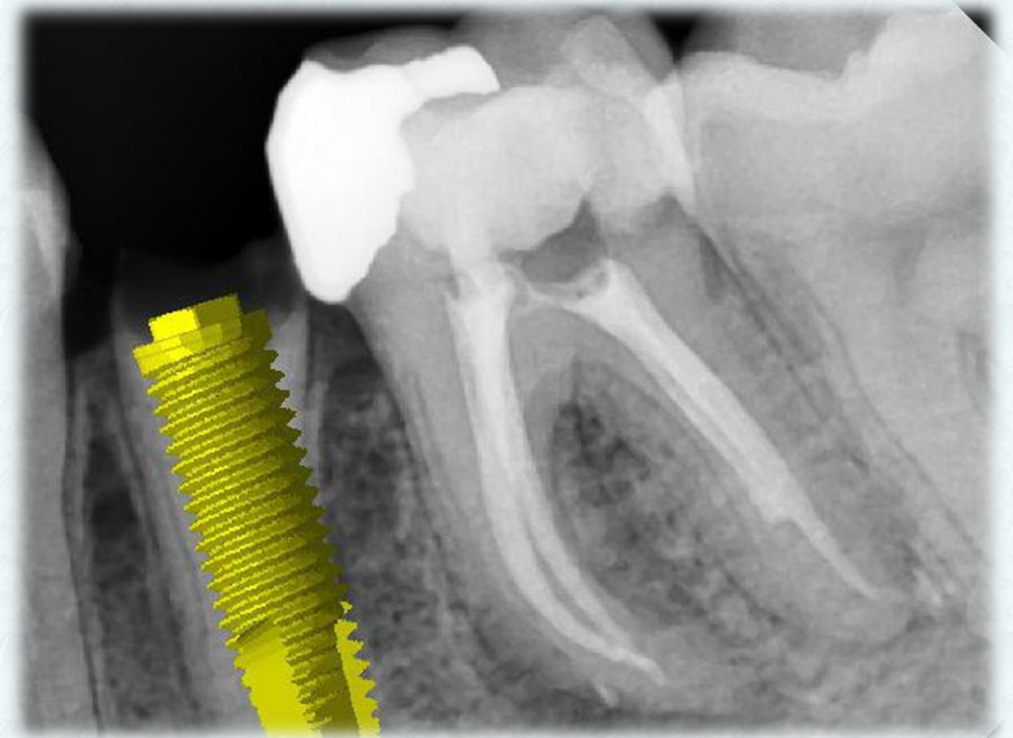- Endodontically consultant
- Secondary caries
- Defective crown
- Implant replacement???



- Endodontically consultant
- Accessibility
- Inf alveolar nerve position
- Resective surgery all around
- Furcation involvement



- Accessibility
- Two surgery procedure in single visit
- Resective surgery in all around





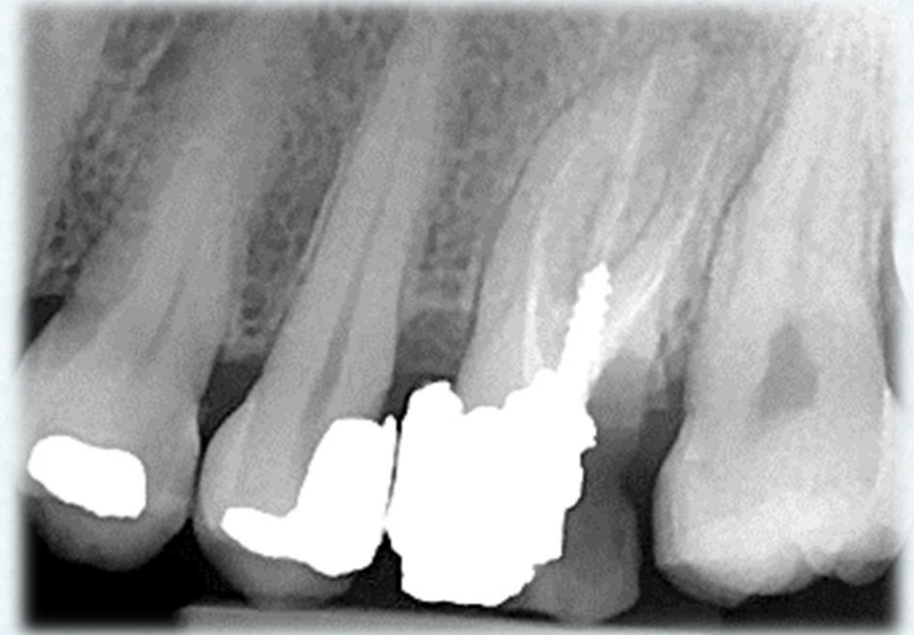# WEALTH ACADEMY

Sunday, February 28, 2021

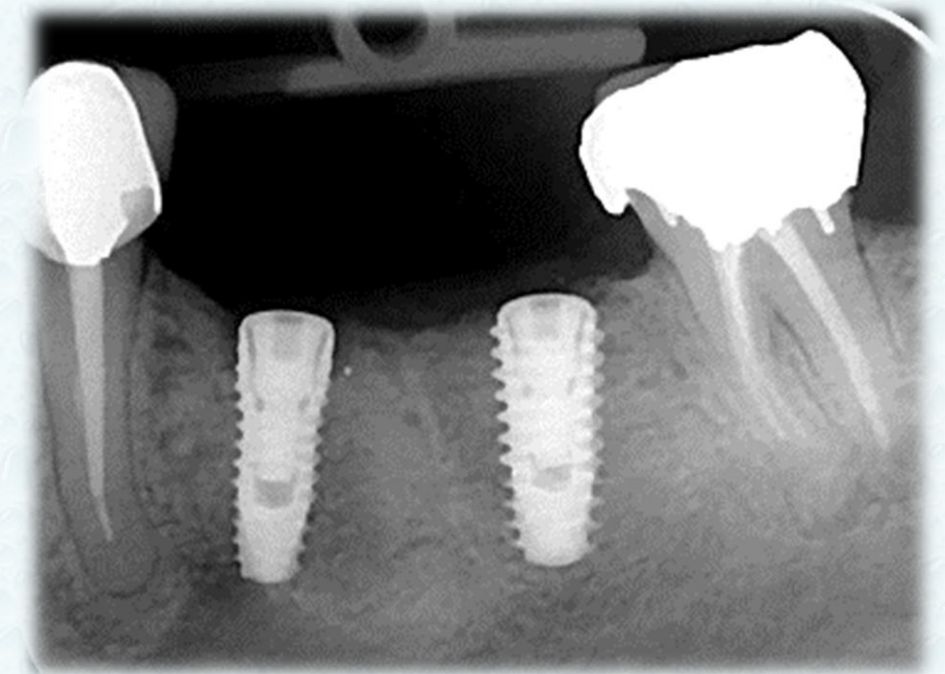
[www.mwmaacademy.com](http://www.mwmaacademy.com)

Presented by Dr. Mojtaba Bayani

- Endodontically consultant
- Sever caries
- Maxillary sinus position
- Implant replacement???

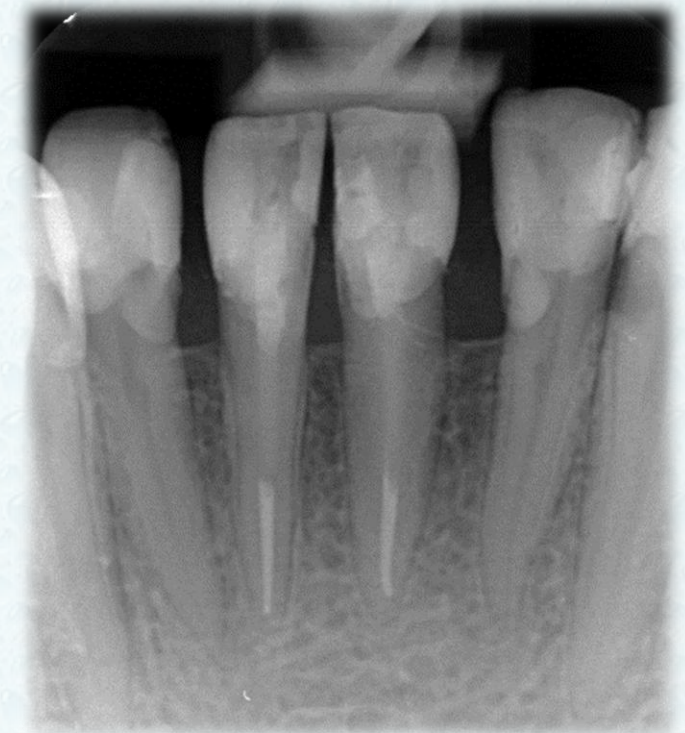

- Endodontically consultant
- Resective surgery near well
- Osseo integrate fixture
- Posterior stop

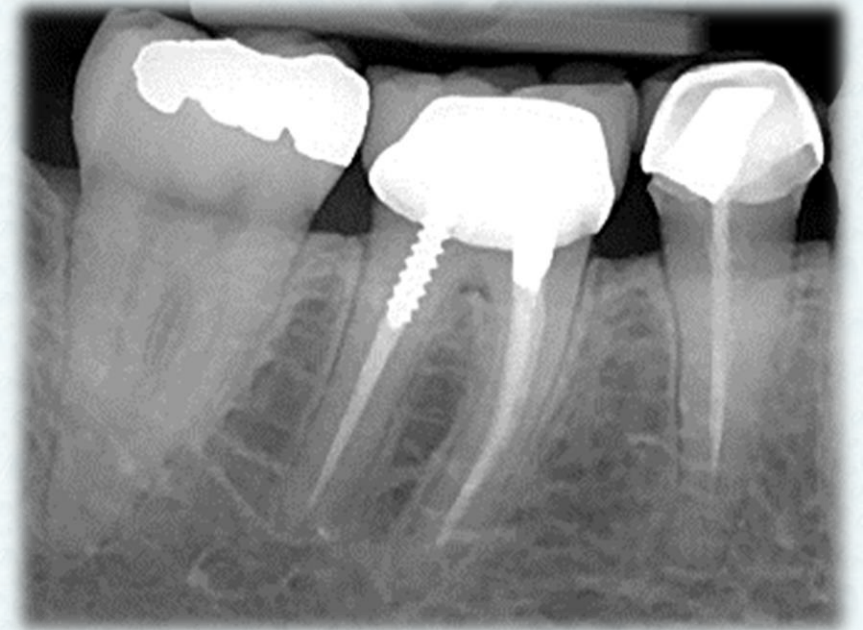




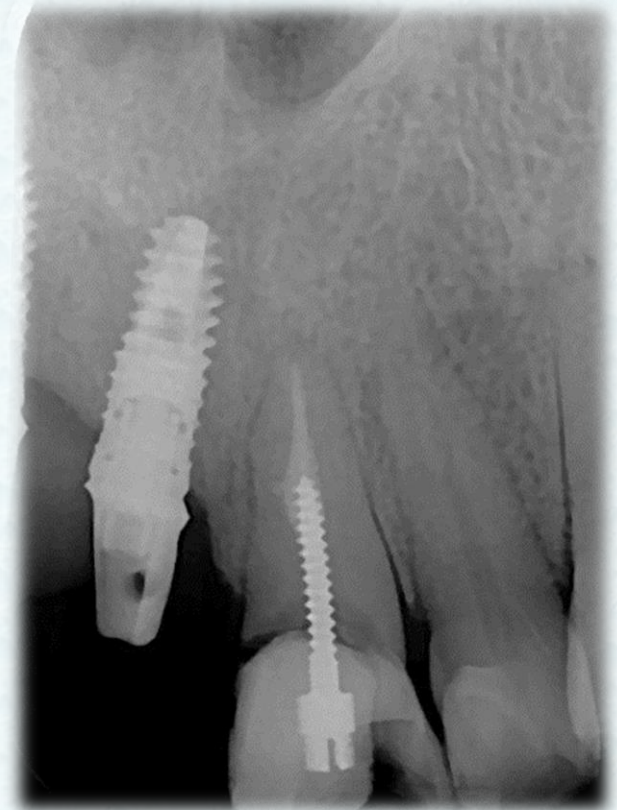- Restorability
- Crown root ratio
- Mobility
- Future crown length
- Replacement with implant???



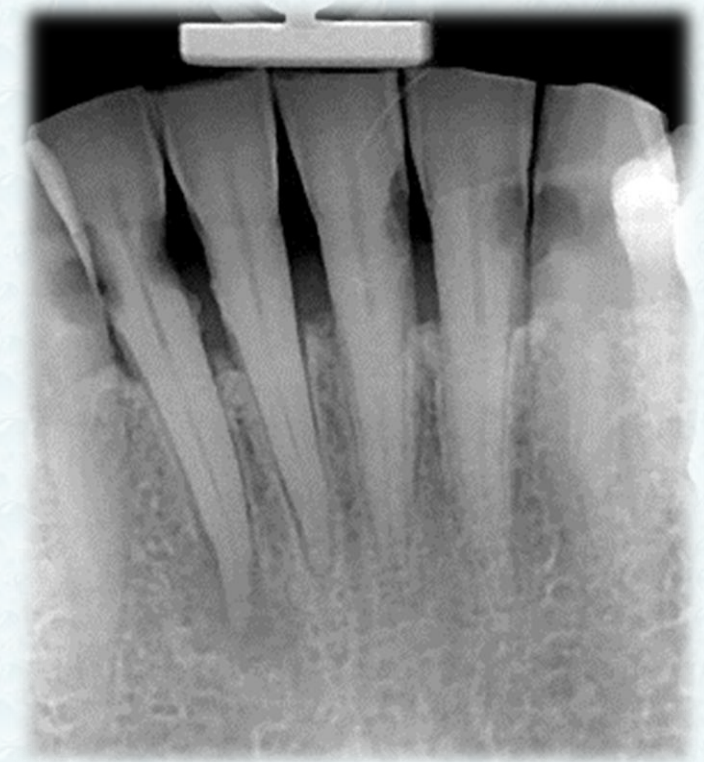
- Endodontically consultant
- Crown lengthening after crown delivery???
- Furcation involvement
- Crown root ratio



- Secondary caries
- Crown root ratio
- Esthetic concern
- Master plan
- Implant position



- Master plan???
- Mobility
- Posterior stop
- Overall prognosis



A person wearing a light blue long-sleeved shirt and a light blue cap is sitting on a sandy cliff, looking out over a vast, calm ocean under a pale sky. The person is seen from behind, with their arms resting on their knees.

SOMETIMES

THE BEST ACTION  
IS NO ACTION



